

## CUTANEOUS NOCARDIOSIS IN A DOG – CLINICAL CASE PRESENTATION

MARCIN GOŁYŃSKI, MARCIN SZCZEPANIK,  
DOROTA POMORSKA AND PIOTR WILKOŁEK

Subdepartment of Diagnostics and Veterinary Dermatology, Faculty of Veterinary Medicine,  
Agricultural University of Lublin, 20-612 Lublin, Poland  
e-mail: marcelgo@op.pl

Received for publication August 03, 2005.

### Abstract

A case of cutaneous nocardiosis in a dog has been described. Clinical diagnosis was made on basis of cytological and histopathological examinations and bacteriological analysis. The dog was treated with cephalexin and successfully cured in 8 weeks. There have been no reports of such cases in Poland so far.

**Key words:** dog, cutaneous nocardiosis, therapy.

Nocardiosis is a disease that is quite rarely observed in dogs. It has been reported in other species, such as cats, horses, cattle, but among them it is not very common as well (4, 10, 17). The disease also occurs in humans usually suffering from immunological deficiencies (2, 8, 11, 14). Nocardiosis appears in several clinical forms. In the case of cutaneous form, pyoderma or pyogranulomatous dermatitis are the most typical symptoms (14). Nocardiosis may also result from respiratory infections when gross lesions are found in the lungs, mediastinum, and pleura, and it may occur as a disseminated form too (14).

Nocardiosis is caused by *Nocardia* sp. It is a Gram-positive, partially acid-fast, aerobic, catalase-positive filamentous branching bacterium (8, 14). The strains most frequently isolated from dogs include: *N. asteroides*, *N. brasiliensis* and *N. caviae* (14). These microorganisms are saprophytes found in soil and infection usually takes place through wound contamination or through respiratory inoculation. The bacteria belonging to this genus may also be found on skin surface and quite rarely on coat in dogs and are treated not as the component of physiological flora, but as the contamination (4). The host organisms with decreased immunity are most sensitive for the infection. Some clinical cases of this disease have been reported in dogs infected with distemper virus (13, 14).

The clinical symptoms accompanying cutaneous form of nocardiosis are as follows: ulcerative nodules, ulcers, fistulas, and cellulitis. In some cases general

symptoms such as fever are noted (6). Haematological examination reveals leukocytosis with left-shift, monocytosis, and hyperglobulinaemia (6). The first lesions are found in places subjected to trauma, i.e. mostly on limbs. In the case of respiratory infection, general symptoms occur such as anorexia and fever as well as dyspnoea and neurological disorders are observed (14). Diagnosis is based on the presence of microorganisms in cytological smears prepared from fine needle aspirates as well as on culture methods and histopathological examination (14).

Therapeutic procedures include surgical removal of infected tissues and antibiotic treatment lasting at least one month.

### Material and Methods

An 8-year-old Rottweiler, male, was referred to the Dermatological Ambulatory of Faculty of Veterinary Medicine in Lublin, in May 2005 for the evaluation of recurrent pyoderma. The first clinical symptoms occurred 24 months before the presentation. Previously the dog was treated with amoxicillin with clavulanic acid. The antibiotic treatment never lasted longer than for two weeks.

The physical and complementary examinations were performed. The microscopic examination of skin scrapings in chlorolactophenol and microscopic hair analysis were carried out in order to exclude parasitosis and mycotic disease. The cytological examination of samples taken from nodules with the use of fine needle aspirate method and from exudative lesions using impression smear method and stained with Diff-Quick were performed.

The blood was collected from the external jugular vein in order to determine haematological and biochemical parameters.

The swabs were taken from exudative eruptions in order to perform bacteriological investigation by culture methods. The material was cultured on agar, blood agar, Sabouraud agar, and Sabouraud agar with

chloramphenicol. The plates were incubated at 37°C for 7 d.

The oligobiopsy of ulcerative nodule, localized on lateral side of the left hind limb, was performed with the use of 6 mm biopsy trepane after the initial sedation (atropine and xylazine) and local anaesthesia with 1% lignocaine. The skin segments were fixed in buffered formalin and routinely stained with haematoxylin and eosin.

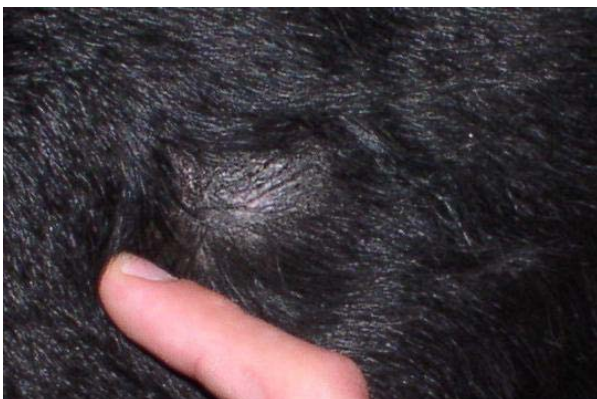Antibiotic resistance testing based on disc diffusion test was performed in order to determine an effective antibiotic for the treatment.

### Results

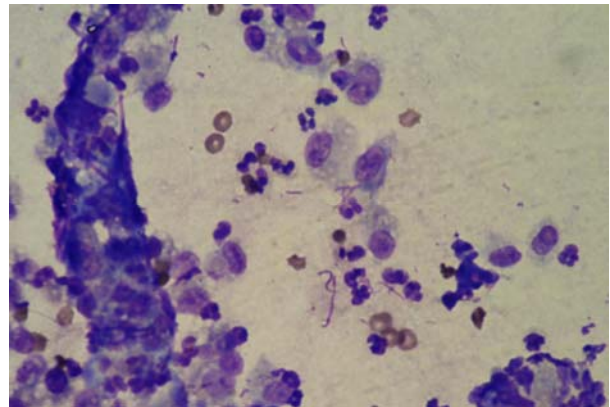
On presentation, the overall status of the animal was good. No other symptoms, apart from skin lesions, were noted. The dermatological examination revealed alopecia, nodules, tubers, fistulas, ulcerations, and lichenizations localized on elbows and lateral side of the left thigh. These lesions were accompanied by localized light pruritus and pain. Haematological and biochemical parameters are given in Table 1.

**Table 1**  
Haematological and biochemical parameters of the examined dog

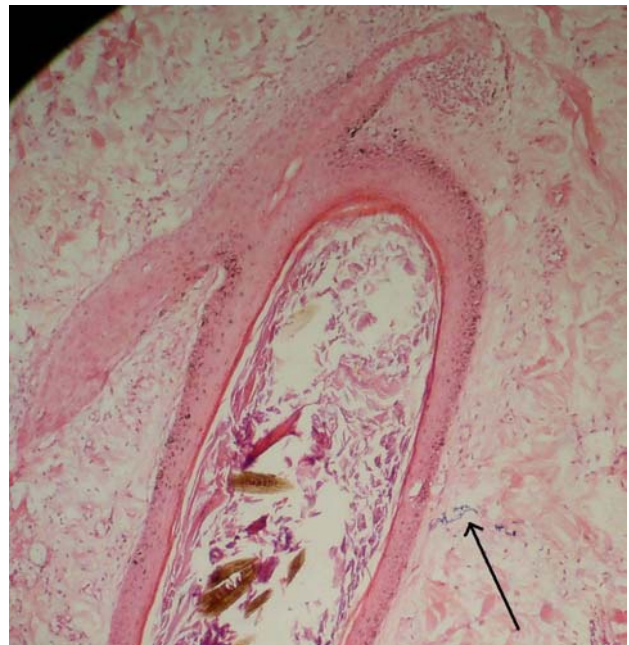BUN	90.7 mg%
Bilirubin	0.18 mg%
AST	32.52 U/l
ALT	31.83 U/l
AP	77.09 U/l
Glucose	93.3 mg%
RBC	7.34 m/mm <sup>3</sup>
PCV	45.1%
Hb	35.3 g/dl
Leukocytes	11.22 m/mm <sup>3</sup>
Segmented neutrophils	6
Polymorphonuclear neutrophils (PMN)	44
Eosinophils	14
Lymphocytes	36



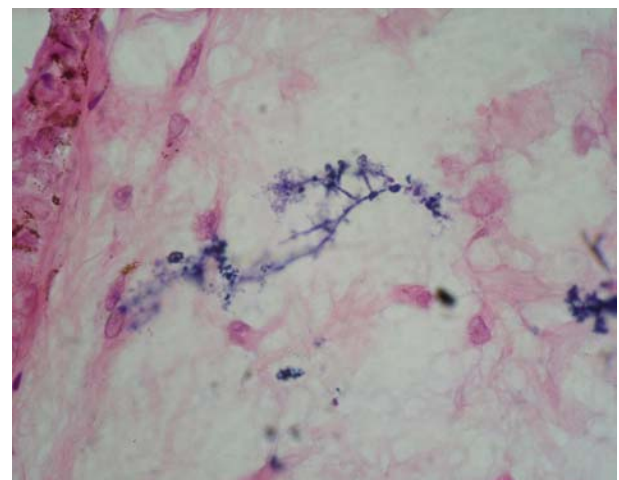
**Fig. 1.** Left elbow, multiple tubercles.



**Fig. 2.** Smear taken from exudative lesion. Numerous neutrophils and macrophages and branching filaments of bacteria are present. (stain Diff-Quick, x 1000)



**Fig. 3.** Histopathological examination, microabscesses, granuloocyte infiltration and filamentous branching bacteria (arrow) are present. (stain H-E, x 100)



**Fig. 4.** Histopathological examination, filamentous branching bacteria. (stain H-E x 1000).

The examination of skin scrapings and microscopic hair analysis did not reveal the presence of dermatophytes and parasites. The cytology revealed numerous neutrophils and branching filaments of Gram-positive bacteria. The histopathological examination revealed filamentous branching microorganisms and microabscesses as well as diffused granulocyte infiltration. The presence of yellow colonies was observed on Sabouraud agar after 7 d. No growth was present on Sabouraud agar with chloramphenicol, whereas after 4 d the growth of chalky white colonies on agar and blood agar plates incubated under aerobic conditions was noted. The microscopic evaluation of these colonies revealed Gram-positive branched filaments. The cultured microorganisms were catalase-positive. The antibiotic resistance tests revealed that the bacteria were sensitive to cephalexin.

Therefore, the dog was treated with cephalexin at the dose of 60 mg/kg b.w., in 2 separate oral doses, and the affected places were washed with 0.5% chlorhexidine three times a day. The dog entirely recovered after 2 months.

### Discussion

Nocardiosis is rarely observed in dogs. The reports of its occurrence are sporadic and mainly refer to countries of warm climate. Such cases were reported in Australia (pulmonary form) and USA (cutaneous form) (6, 16). There have been no reports of such cases in Poland so far.

The disease should be suspected when deep pyoderma accompanied by the formation of nodules, ulcers, and fistulas is observed. While taking history data, special attention should be paid to previous trauma and localization of primary eruptions. Complete diagnosis should be based not only on clinical symptoms, but also on complementary examination. Differential diagnosis includes other bacterial diseases with similar course, such as actinomycosis, and deep mycotic infections, e.g. sporotrichosis, which quite often manifest in a similar way (18).

The recommended complementary evaluation carried out in order to confirm diagnosis includes cytology and histopathological examination. Microscopic specimens reveal branched Gram-positive filaments present in intra- and intercellular spaces (12). In cytological preparation neutrophils are predominant (8) and individual macrophages and lymphocytes may also be found (12). In this case the similar picture was noted in the cytological evaluation of fine needle aspirates.

Histopathological examination reveals analogous picture to this associated with infection with pyogenic bacteria (1). In this case the histopathological preparations revealed microabscesses and granulocyte infiltration that are typical for this disease. The presence of filamentous branching bacteria is also of great importance.

Bacteriological investigation by culture methods presents another possibility for establishing final diagnosis. However, it usually demands a significant period of time devoted (growth may be observed after 2

days up to even several weeks, but usually first colonies are found just after 3-5 d) (5, 1) and therefore treatment is carried out according to results of cytological and histopathological examinations (16). Materials may be cultured on chocolate agar, blood agar, and Sabouraud agar under aerobic conditions at 37°C (7, 8). *Nocardia* sp. grows in aerobic atmosphere whereas similar bacteria of *Actinomyces* genus demand anaerobic or microaerophilic conditions (15). On blood agar medium, the colonies are chalky white and have a powder-like surface (1, 7) while on Sabouraud agar the colonies are dry, shrivelled, yellow in colour which in time turns into orange (7). In the case of diagnosed nocardiosis, many authors recommend surgical approach as well as antibiotic treatment (6, 9, 12, 14). In this clinical case presentation, long-term antibiotic treatment with cephalexin and topical applications of an antiseptic alone proved to be effective. In human as well as in veterinary medicine, potentiated sulphonamides are thought to be useful (1, 4, 8, 9). Gentamicin, ceftiofur, and amikacin are also operative (13). *N. nova* is generally sensitive to macrolides, penicillin, and ampicillin. *N. asteroides* is resistant to macrolides and penicillins (5, 14). Other authors report that treatment with amoxicillin and ampicillin is effective (16). Duration of therapy, which must last at least 1 month, is particularly important (14).

### References

1. Corti M.E., Fiotti M.F.V.: Nocardiosis: a review. *Int J Inf Dis* 2003, **7**, 244-250.
2. Gallant J.E., Ko A.H.: Cavitory pulmonary lesions in patients infected with human immunodeficiency virus. *Clin Infect Dis* 1996, **4**, 671-682.
3. Guaguare E., Prelaud P.: A practical guide to feline dermatology. Merial, 1999, p. 68.
4. Harvey R.G., Lloyd D.H.: The distribution of bacteria (other than *Staphylococci* and *Propionibacterium acnes*) on the hair, at the skin surface and within the hair follicles of dog. *Vet Dermatol* 1995, **6**, 79-84.
5. Hollick G.: Isolation and identification of aerobic actinomyces. *Clinic Microbiol Newsletter* 1995, **17**, 25-29.
6. Kirpensteijn J., Fingland R.B.: Cutaneous actinomycosis and nocardiosis in dogs: 48 cases (1980-1990). *J Am Vet Med Assoc* 1992, **5**, 917-920.
7. Malicki K., Binek M.: *Zarys Klinicznej Bakteriologii Weterynaryjnej*, Warszawa, Wydawnictwo SGGW, 2004.
8. Maraki S., Scoulica E., Alpantaki K., Dialynas M., Tselentis Y.: Lymphocutaneous nocardiosis due to *Nocardia brasiliensis*. *Diagnost Microbiol Inf Dis* 2003, **47**, 341-344.
9. Marino D.J., Jaggy A.: Nocardiosis. A literature review with selected case reports in two dogs. *J Vet Intern Med* 1993, **7**, 4-11.
10. Pascoe R.R.R., Knottenbelt D.C.: *Manual of equine dermatology*. London, W.B. Saunders, 1999, p 115.
11. Pelzer K., Tietz H.J., Sterry W., Haas N.: Isolation of both *Sporothrix schenckii* and *Nocardia asteroides* from a mycetoma of the forefoot. *Br J Dermatol* 2000, **143**, 1311-1315.

12. Raskin R.E., Meyer D.J.: Atlas of canine and feline cytology. Philadelphia, W. B Saunders Company 2001, p. 44.
13. Ribeiro M.G., Aguiar de D.M., Paes A., Megid, A., Giuffrida R., Nari de G., d'Arc Moretti L., Ueno T.E.H.: Nocardiose cutânea associada à cinomose em cães. Relato de dez casos. *Clín Vet* 2002, **39**, 34-42.
14. Scott D.W., Miller W.H., Griffin C.E.: Small Animal Dermatology. Philadelphia, W.B Saunders Company 2001, p. 323-324.
15. Shimizu A., Ishikawa O., Nagai Y., Mikami Y., Nishimura K.: Primary cutaneous nocardiosis due to *Nocardia nova* in a healthy woman. *B J Dermatol* 2001, **145**, 154-156.
16. Sivacolundhu R.K., O'Hara A.J., Read R.A.: Thoracic actinomycosis (arcanobacteriosis) or nocardiosis causing thoracic pyogranuloma formation in three dogs. *Aust Vet J* 2001, **79**, 398-402.
17. Sulieman M.S., Hamid M.E.: Identification of acid fast bacteria from caseous lesions in cattle in Sudan. *J Vet Med* 2002, **49**, 415-418.
18. Szczepanik M., Śmiech A.: Sporotrichoza w przebiegu głębokiej piodermii owczarka niemieckiego. *Mag Wet* 2004, **13**, 36-40.